



THE COLLEGE OF
OPTOMETRISTS

Stage Two

Overarching case scenario 18

AGE AND GENDER Female aged 68 years

ETHNIC BACKGROUND. Caucasian

OCCUPATION AND HOBBIES Retired Teacher: driver: enjoys crosswords, jigsaws and gardening

PRESENTING SYMPTOMS AND HISTORY : Routine eye examination (last test 2 years ago). Reports distance vision not as good; for last few months for near vision, the print blurs intermittently. Wears Rx for driving. Noticed floaters in the right eye for the last 3 weeks, flashing lights noticed at first but not in the last two weeks. No headaches.

GENERAL HEALTH AND MEDICATION : Good, takes tablets for raised blood pressure.

PRESENT Rx, CENTRATION AND ACUITIES with

Current Rx D28 Bifocals - Good condition - Distance OC 65mm

R -3.00/-0.75x10 6/9 Near Add +2.00 N5

L-2.75/-1.00x170 6/12 Near Add +2.00 N 5

Vision 6/60 R&L

PD/NCD 64/61 at 40 cm

PINHOLE VISION RE: 6/9+ LE 6/9

REFRACTION

R -3.50/-0.75x15 6/6 Near Add +2.25 N5@40cm

L-3.50/-0.75x180 6/6- Near Add +2.25 N 5@40cm

ACCOMMODATION. R 1D L 1D

BINOCULAR STATUS

Distance cover test with Rx: no movement observed: Maddox Rod 2 *prism* exophoria

Near cover test with Rx: 8 prism exophoria and 4 prism base IN LE to align bars on near Mallett

MOTILITY Full and smooth, no diplopia

CONVERGENCE : NPC 10cm

PUPIL REACTIONS : Direct and consensual reflexes present

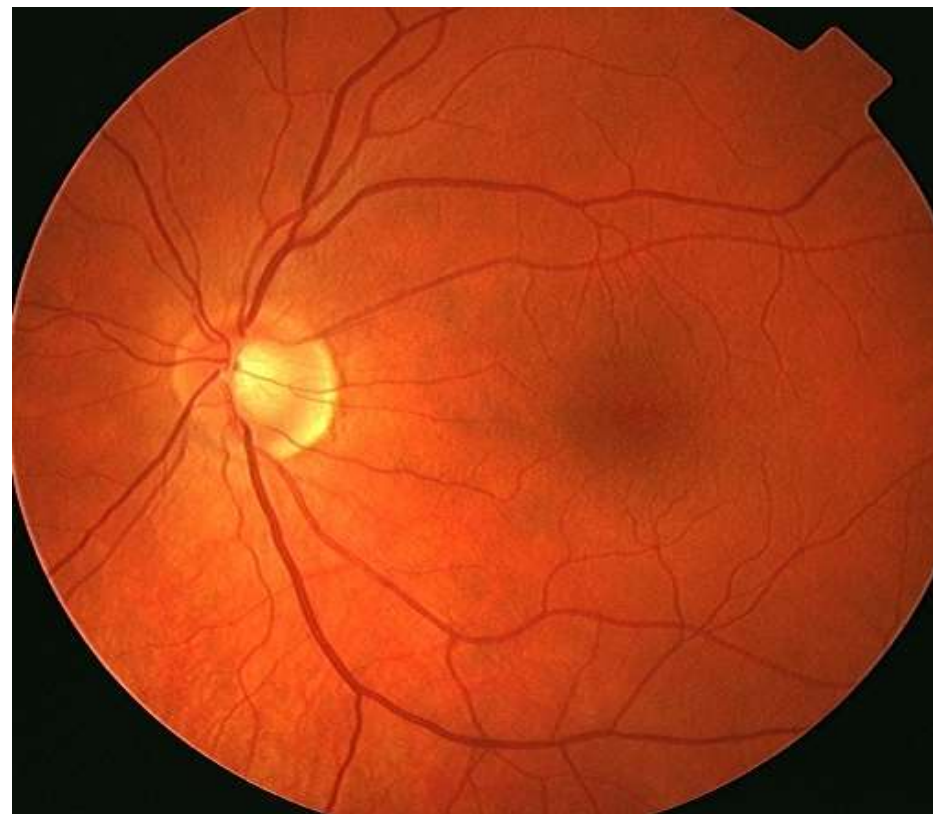
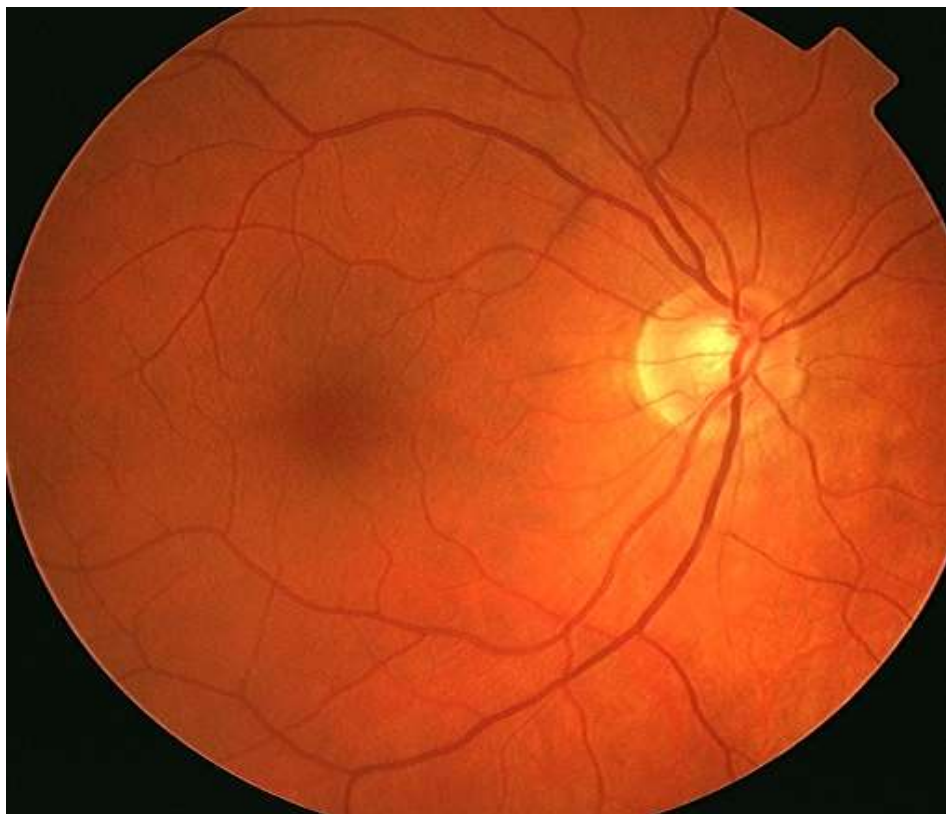
FUNDUS EXAMINATION : see attached

FIELDS Tested using Henson 3000: Full R&L

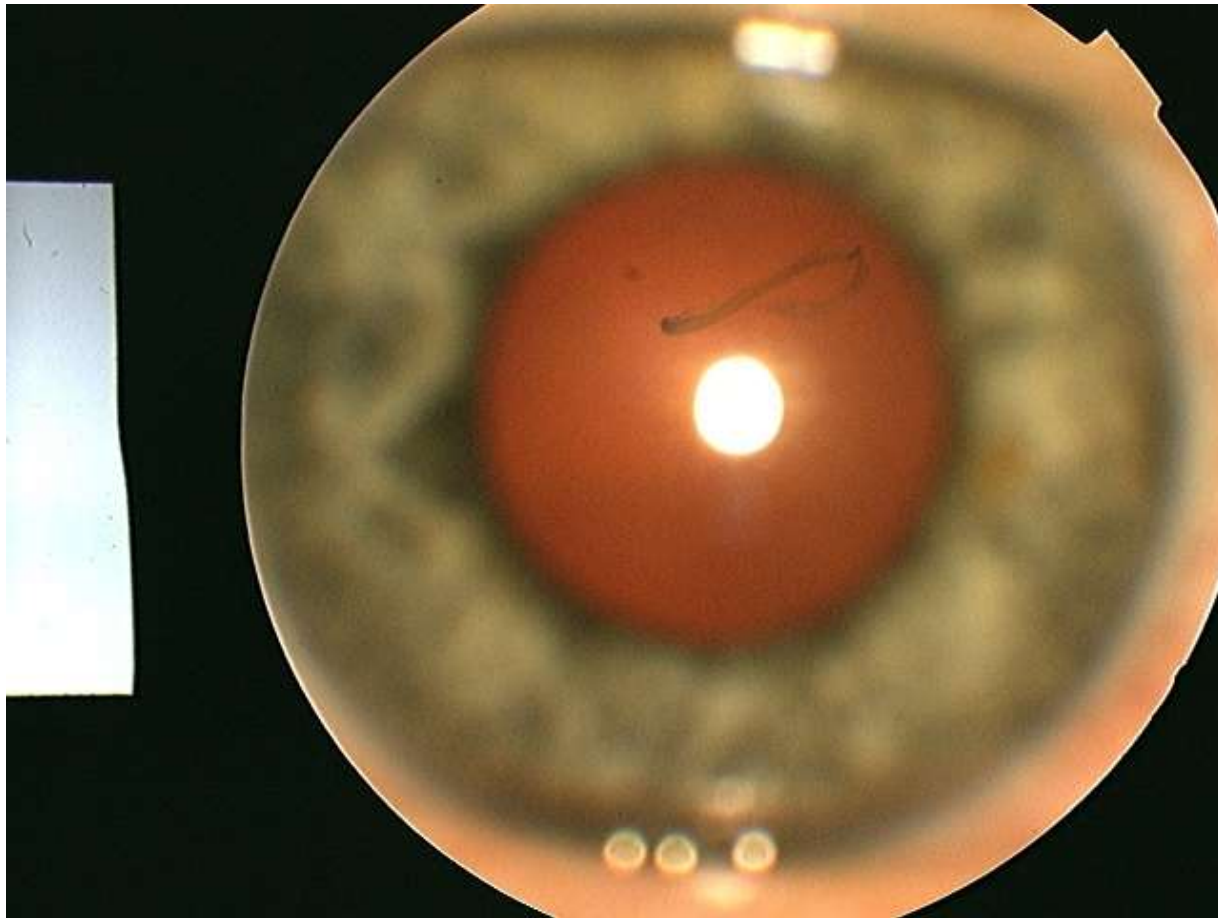
IOP RE 21,20mmHg, LE 20,20mmHg Perkins 9.30 am

EXTERNAL EYE EXAMINATION see attached

Fundus Image



External Eyes RE



R18

External Eyes

